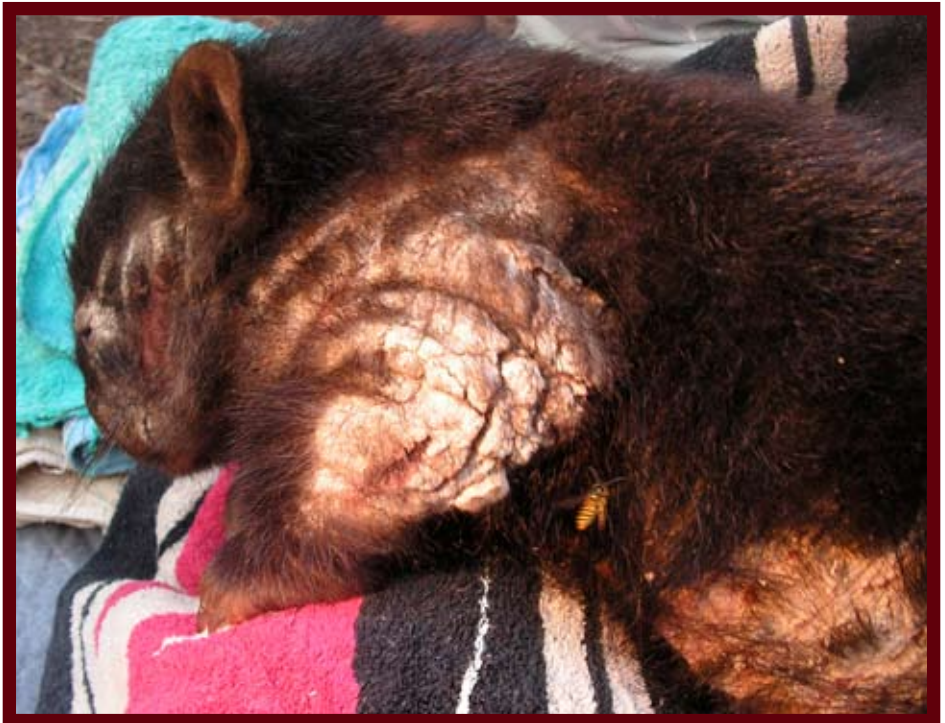

**Identifying mange  
and  
the capture and  
transport of manged  
and injured  
wombats.**



## Why is it important to recognise mange?

It is important to be able to identify if a wombat is manged or not as it often informs the fate of the wombat:

Some shelters will not take manged wombats but may take other injured wombats;

Initial treatments may be inappropriate if the condition of the wombat is inadequately identified;

Further treatment may be inadequate or simply wrong if the shelter or vet is not able to identify the problem;

Field treatment may be commenced inappropriately;

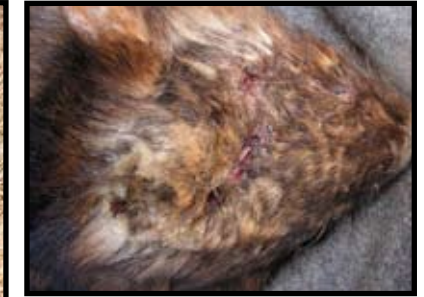Euthanasia may be inappropriately prescribed;

Personal protection and hygiene may be either inadequate or unnecessarily onerous;

Capture may not be necessary.

The identification of mange may appear to be obvious but it is not always easy so.

Take a moment to look at the photos to the left and identify which ones you think are showing symptoms of mange.



2

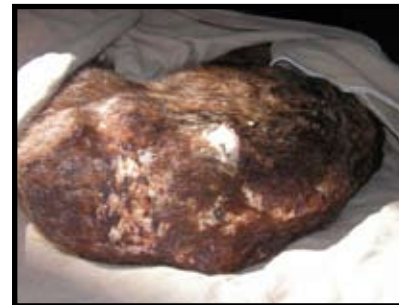1



4



3



6

5



In the field, any of the wombats on the previous page, with the exception of wombat 4, would be identified as needing to be captured, assessed and possibly go to a wildlife shelter and/ or vet.

Of the wombats pictured nos 3, 4 & 5 are manged. No 2 is burnt and nos 1 & 6 are dog attacks. Wombat 3 has been manged for quite some time and has been treated in the field. We will look at her in more detail further on. Wombats 3 and 6 did not survive.

### What is mange?

Mange is caused by an infestation of tiny mites called *Sarcoptic Scabii*. Wombats are hypersensitive to the mites and the excessive irritation that results leads to the severe compromising of the wombat's largest organ - the skin.

*Please note.*

*Some of the following images of wombats may be distressing. All of these wombats were brought to the Hepburn Wildlife Shelter alive because we specialise in the treatment and critical care of adult wombats.*

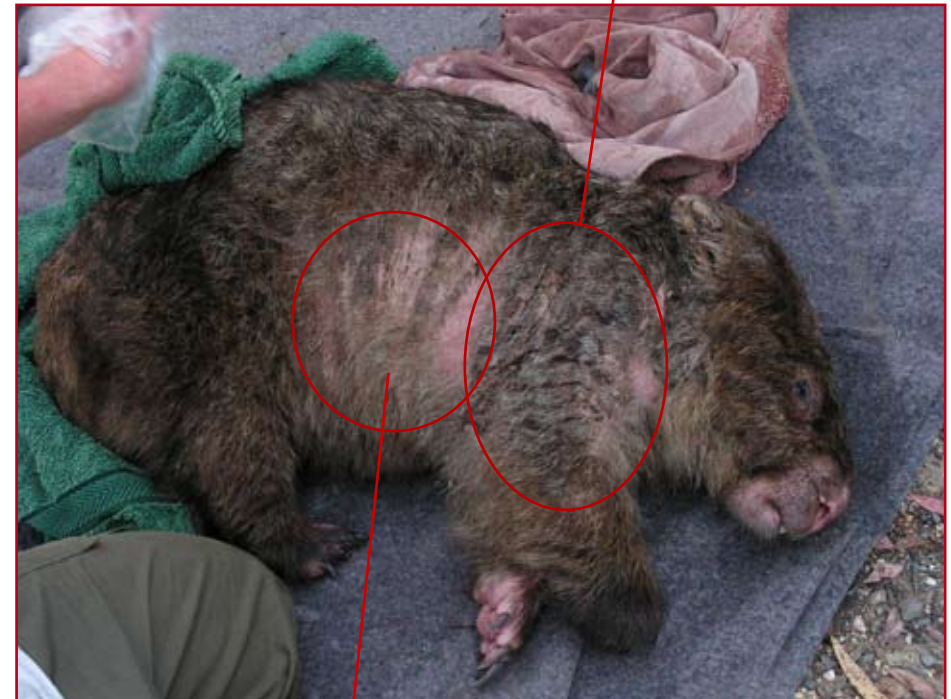*Wombats are treated with veterinary supervision and assessed according to our ability to actually treat the problem in relation to their levels of pain, discomfort and distress and our ability to manage those considerations. They are then assessed on their potential of recovery and ability to survive and be returned to the wild.*

### Identifying Mange

There are some simple visual signs that will enable you to tell the difference between a manged wombat and a wombat that has been wounded by other wombats, dogs, car attack or fire.

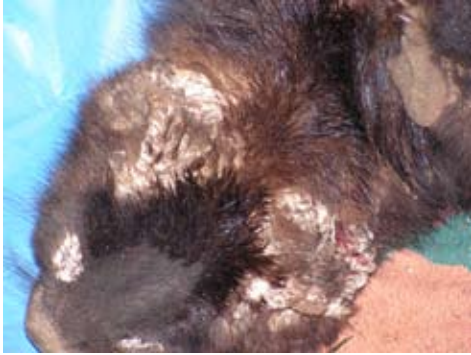***1: Mange will be visible from a distance only in the later stages of infestation. It will appear either: -***

as a dry, raised crust,



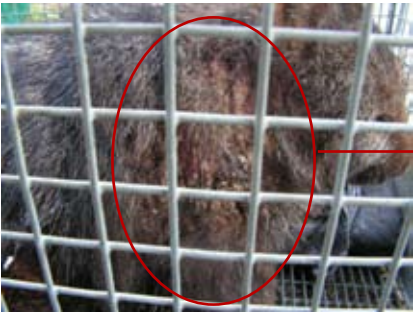or as a thin coating of yellow or cream coloured scales that is sticky and moist on the skin.

**Crusting may or may not be accompanied by fur loss.**

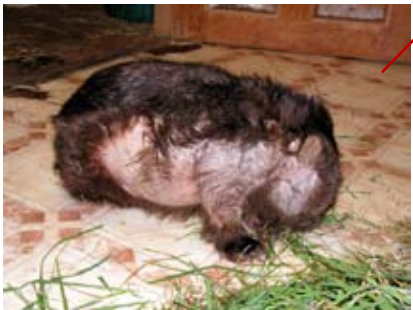

Crust is formed from the disruption that the mites cause to the healthy formation of the epidermis - the outer layer of the skin. Generally, the longer the wombat has been infested with the sarcoptic mites, the thicker the layers of crust become.

**2: Visible mange infestation follows a well defined pattern on the wombat. There are very few exceptions to this.**



Visible crusting initially forms laterally along the wombat, starting on the fore legs and shoulders and moving around the back of the neck.

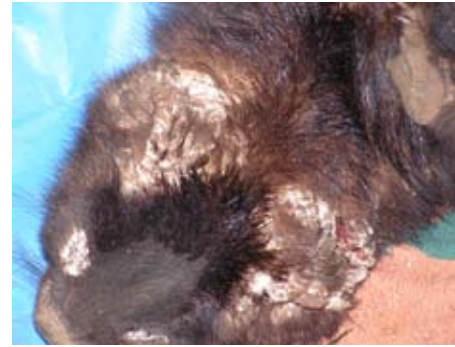


This is the same wombat as above but a couple of months into treatment. The fur loss has been caused by mange that was once there and the pattern clearly shows how the mange had spread laterally down the sides of the wombat.

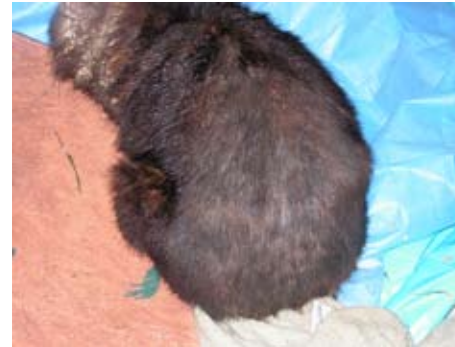

Looking at the wombat from the front you can see that there has been no fur loss and identifiable spread of mange along the top of the wombat.

**3. Mange does not visibly manifest symptoms along the back or the back protective plate of the wombat.**



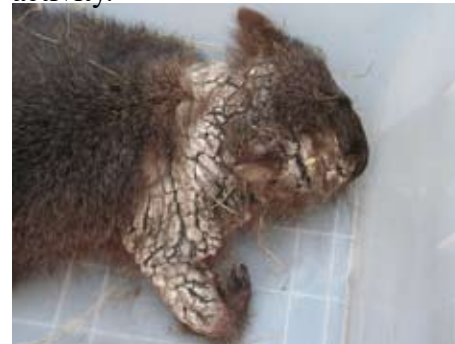This wombat clearly has a severe infestation of mange. It also shows how a mange infestation is usually quite even on both sides of the wombat. Often one side will be a little worse than the other but the spread is mirrored very consistently.



The same severely infested wombat as above, shows NO infestation along the back of the wombat and NO infestation on the back protective plate of the wombat. This is a clear and generally reliable indicator.

**4. Mange infestation moves laterally forward along the sides of the head.**

Note on this wombat the lack of mange manifestation along the back and fore head. This does not mean there are no mites in those areas but that there are far fewer mites and that you can not see the results of their activity.



**5. Fur loss is not a reliable indicator of severity of mange infestation.**



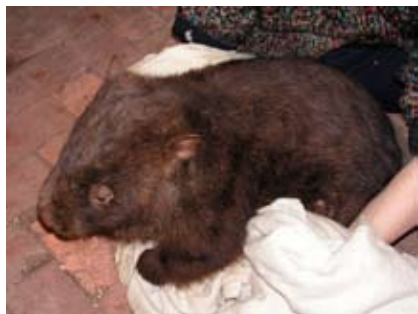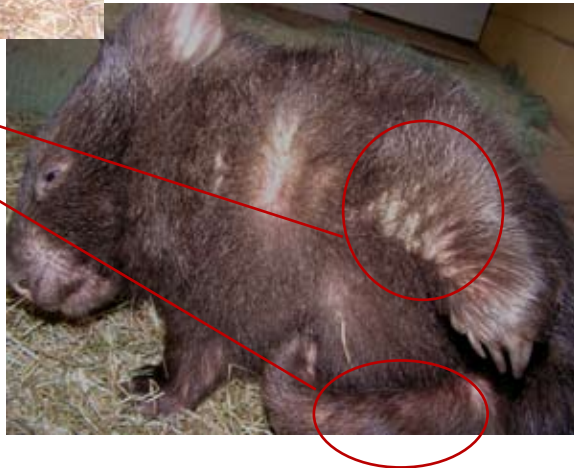
This young wombat appears not to be infested with mange.

On closer inspection it can be seen she is dangerously infested with mange that will eventually lead to her death

Crusts are forming on the fore legs

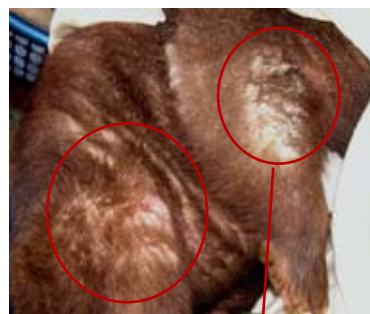Inflammation and irritation on the hind legs

The belly of this wombat was also showing signs of advanced infestation - thin layer of yellow/ cream sticky crust.



It's hard to believe that these two photos show the same wombat. On closer inspection the mange is again obvious.

Inflammation, / irritation and moist crust on lateral body, belly and on the hind legs



Crusts have formed on the fore legs

In cases where mange infestation is not visible with out close inspection, the behaviour of the wombat may give you the information that tells you something is amiss, weather it be mange or not.

A wombat requires closer inspection if:

It is seen regularly grazing during the day;

It is wandering outdoors during the day and appears dazed and confused;

It is sheltered in a shed or drain rather than a burrow;

It is sleeping or resting above ground during the day;

**Deciding to treat a manged wombat in the field rather than capturing the wombat for captive care.**

Some people decide to treat wombats in the wild by pouring acaracides (isecticides that kill mites and fleas) on the wombats. This can arrest the mite infestation and buy the wombat a little more time. However there are many concerns with this path of treatment - the main being:

- the ability to sufficiently and regularly dose the wild wombat;
- inability to moniter outcomes;
- inability to treat secondary conditions resulting from mange infestation;
- lack of success to completely treat the mite infestation.

After recent fires a number of manged wombats were captured and taken into care. These wombats showed signs of advanced mange infestation but without the crusting or fissuring. Signs were - extensive fur loss; thickened and couliflour ears; crust about the eyes, loose and rough, dry skin and emaciation. Some wombats showed signs of fur regrowth. These wombats had been treated in the field either by the ash or with acaricides.

The following two wombats had been treated for mange in the field at some stage before coming into care.

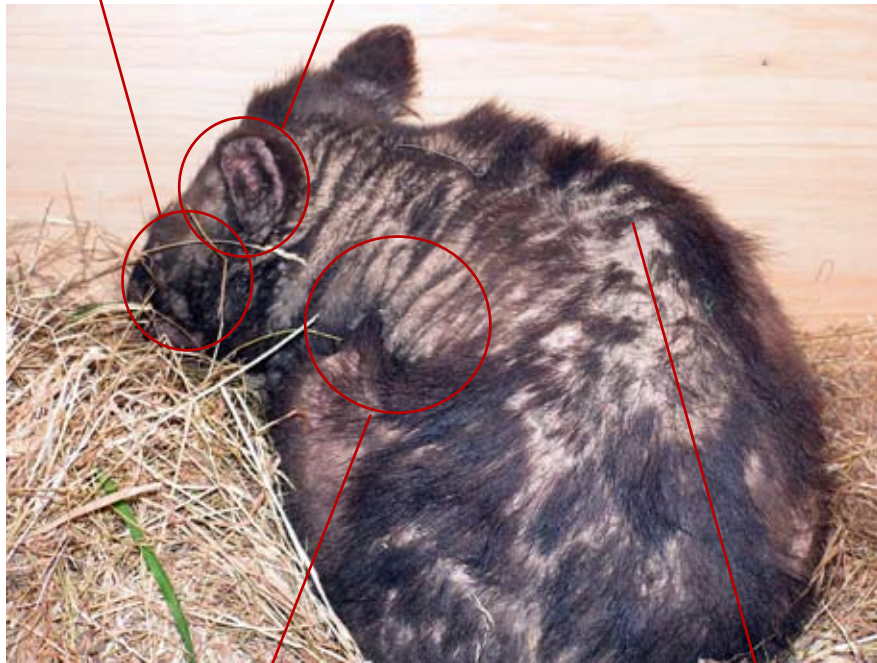
### **Wombat 1**

Thick crust still clings to the cheeks

Cauliflower ears that have been thickened, pitted and scarred from having once been heavily crusted.



The wombat below would once have had ears that looked like this.



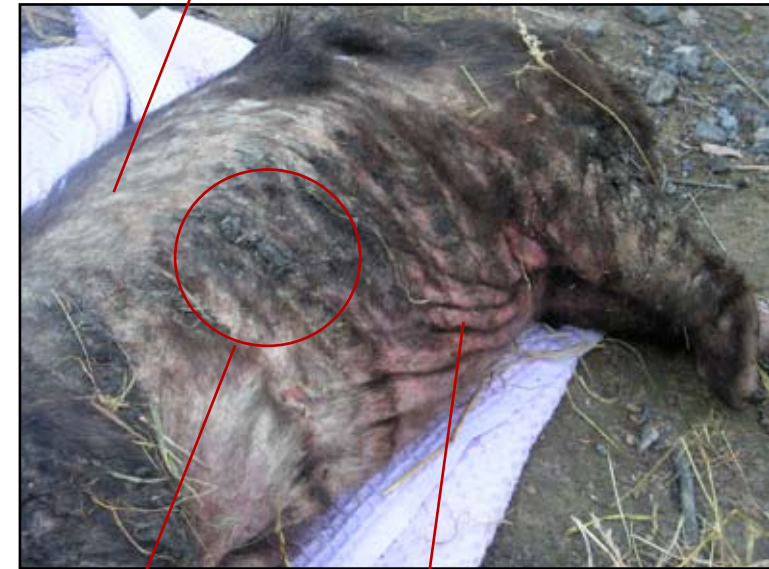Extensive fur loss but little or no signs of continuing mite activity. The skin appears loose and 'folded'

Vertebrae very pronounced indicating emaciation

The extensive fur loss across the back is most likely a result of lice infestation, malnutrition, old scarring from normal wombat encounters.

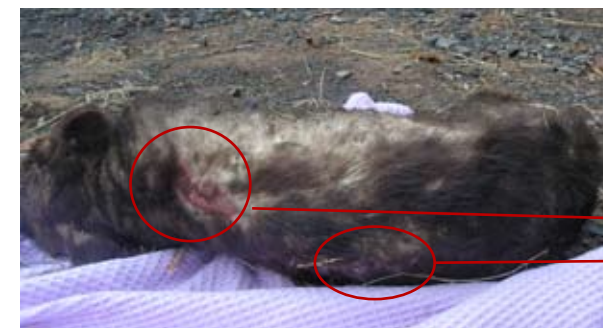### **Wombat 2**

Fur regrowth indicating eradication of significant mite infestation in this area



Small amounts of arrested crusting due to ash

Red and inflamed skin indicating increasing and significant mite activity. Notice how loose and 'folded' the skin is

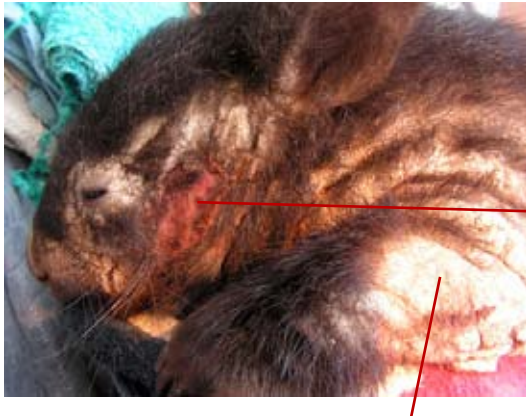

This wombat is clearly emaciated. Lateral fur regrowth is indicated.

The raw wounds on the back are burns.

## Over all health of mange infested wombats.

Wombats that have been heavily infested with mange will more often than not have other conditions that need attention. The compromised condition of the protective organ - the skin - provides opportunity for bacteria and fungal infections to enter the body. Fluids are lost through fissuring of the crust that exposes muscle tissue, stress and decline in the integrity of the skin.



Wombats will scratch off chunks of crust which causes raw and painful wounds.

The moist protective environment underneath this crust is ideal for fungal and bacterial growth.

Necropsies of manged wombats have revealed unhealthy lungs that have been congested with blood, scarring on the lungs and scar tissue that has 'glued' the lung to the sides of the chest cavity. Fungal yeasts were found in the lungs, which is not abnormal for wombats, but may become problematic for an ill wombat. Wombats from fire grounds showed black deposits of carbon in the lungs.

Muscle tissue samples indicated the possibility of peracute myopathy which is caused over a short duration of time (a few hours), possibly at capture and/ or transport.

The majority of wild wombats with severe mange infestations are underweight to the point of being emaciated (50% of expected body weight).

## Mistaken Identity

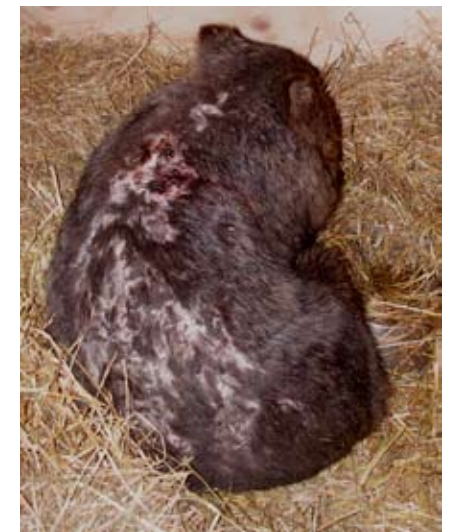Most wombats suffering from ugly, smelly, maggoty wounds, and who are walking about in the day time are usually assessed as having mange. The following are all cases that were mistakenly identified as mange.



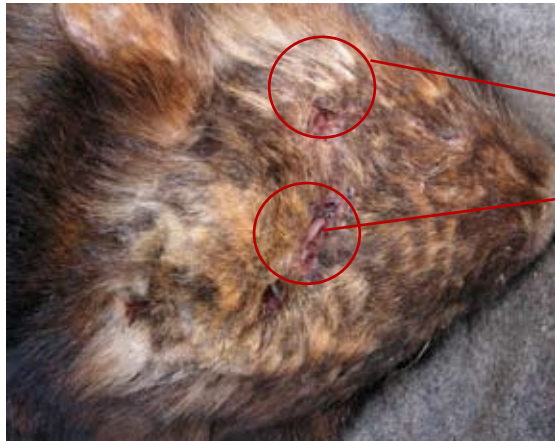Head wound from an excavator bucket digging up a burrow. The wound was filled with dirt and difficult to identify but there are absolutely no other signs of mange anywhere on the body. This wound is placed where mange would not be visible without the wombat being heavily crusted. This wombat should have been euthanased at capture point.



The wombat below is also a fire victim and has been attacked by dogs. Again no lateral signs of mange on the body.

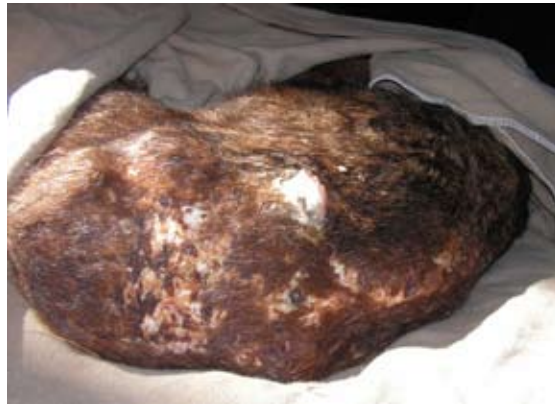

The wombat above has a full thickness burn down the length of its back. There are no lateral signs of mange and the visible wound is again on the part of the wombat that does not show visible indicators of mange infestation.



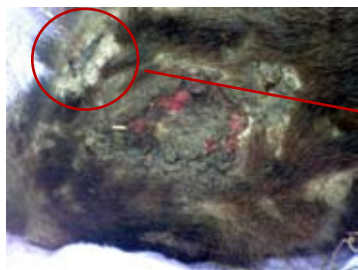This wombat has been attacked by dogs. The deep tooth shaped penetrating wound and flesh ripping can be seen on the fore head.

The wound pattern on the back is not indicative of mange infestation. The white patches are scarred skin and the fur discolouration also indicates older wounds.



Wombat attacks look very similar to dog attacks and it is often the the shape of the penetrating wound that will reveal the attackers identity.

Wounds from wombat attacks are generally seen around the back protective plate, the back of the neck and the fore head. This is almost identical to a dog attack pattern. The wombat above appears to have been attacked several times over time. The attacks may have been from wombats and dogs at different times.



The wombat to the left is showing signs of mange. Can you see it?

Crusty white build up around the eye is mange related. The wound on top of the head is not mange related and is either a burn or a badly directed bullet wound.



This young wombat has had her wounds cleaned up but when she was taken to a vet by a rescuer, who said she was manged, she smelt and looked putrid as her wounds were badly infected.

The vets were reluctant to handle her and she waited over twelve hours for treatment which eventually came from a shelter that lost patience with the vet and just went and picked her up. Can you tell what was likely to have caused wounds like this? A dog or a fox was most likely involved.



It is a little harder to identify the reason for the patchy fur loss on this wombat just by looking at her. On closer inspection it was determined to be a lice infestation.



Lice on a wombat can be clearly seen running about the skin. The debris they leave behind can also be seen and although the skin may appear a little dry and scaly it does not generally look inflamed and build up of crusts is not observed. Lice infestation will be observed over the entire body.

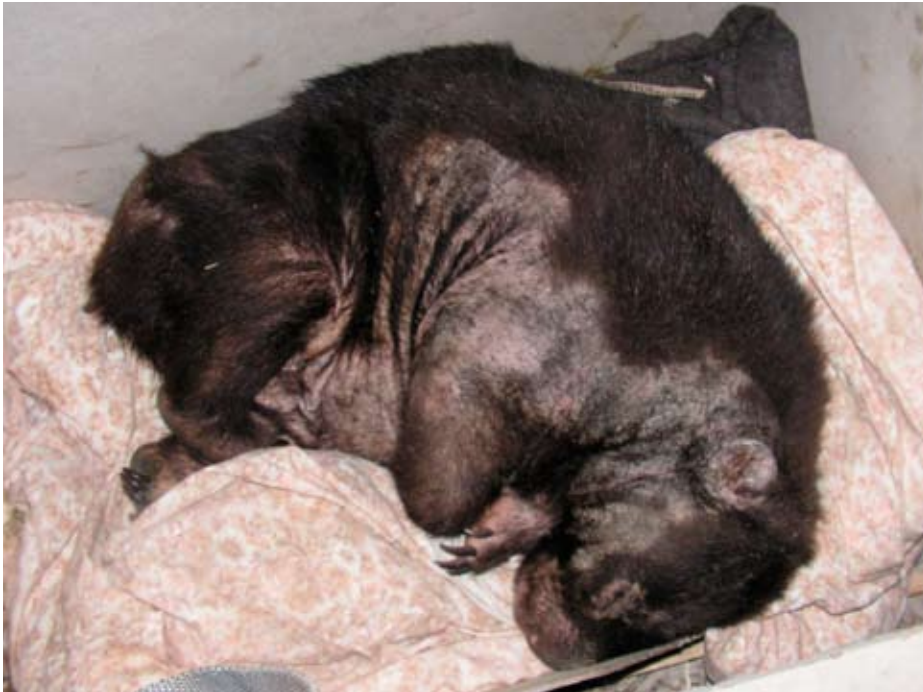It was the location of this wombat, not the way she looked, that tipped rescuers off that she needed assistance. She was wondering around parklands in the outer suburbs of Melbourne - a long way from suitable wombat habitat.

Once rescued, the lice infestation was mistaken for mange.

## Fire, ash and Mange

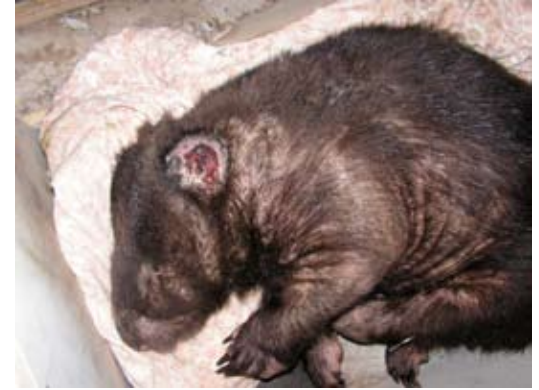This girl below was brought into the shelter one year after the fires in King Lake. She has clearly had extensive mange as the pattern of fur loss indicates. We made enquiries with local rescuers and shelters in the area and nobody knew of this girl having been treated in the field. She was located in an area remote from any human housing or activity. We suspect that the fine ash from the fires has treated the mange. The very fine ash would have smothered the mites very effectively. Perhaps heat may also have a role to play.

This wombat was identified as being severely manged - what do you think?



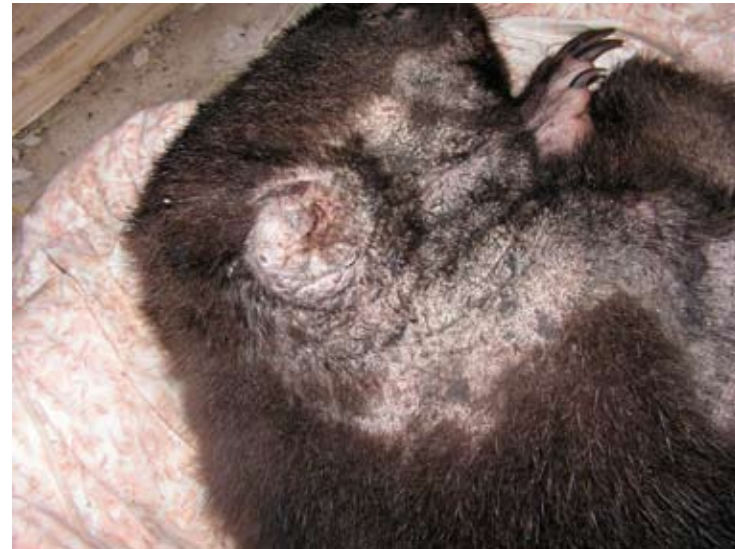On closer inspection there were some remnants of blackened and ash coloured crusts but mild for any wombat, especially one that had obviously been manged to the extent that she was.

It can be seen that she has very good fur regrowth. It was hard to sitinguish between scarring from mange fissuring and scarring from burns and really only the locality of the scares could provide us with clues to her history.



Notice the ears on this wombat and compare them to photos of manged ears on page 10. This wombat does not have manged ears, she does not have any external ears in fact, they have been burnt off. The 'couliflour' effect that we are seeing here is the inner cartilage and tissue of the ears responding to being exposed due to the lack of the external ears.

This wombat was also blind, possibly from smoke and ash. Despite all that she had survived for over a year in harsh conditions, manged, burnt and recovering. What actually killed her was a dog bite to her back leg that had become toxic and she died from septicemia.



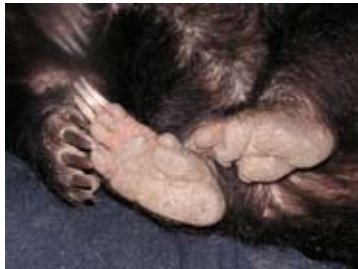There are other indicators that tell will give you clues to the wombat's situation.

### ***Dirt in the Fur***

If there are no fragments of soil or dust in the fur then the wombat is unlikely to be living in a burrow. This can be an indicator that something is wrong and that the wombat may be displaced. Often severely manged wombats will abandon burrows and seek shelters above ground or in drain pipes. Wombats disoriented by illness such as toxoplasmosis and septicemia, may also have fur and skin clean of dirt. Hand raised wombats that have been badly rehabilitated and released are often displaced and show no signs of burrowing.

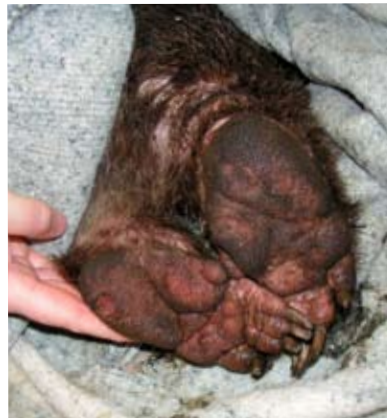### ***Feet***

The feet of the wombat are good indicators of displacement, especially displacement due to poor rehabilitation and unsuitable release.



The feet of a healthy wild wombat, or a wombat properly prepared for release, should be grey and calloused as can be seen to the left.

The photo to the right is a picture of the feet belonging to the wombat with the lice infestation. The pads are raw with inflammation and pitting from walking on hard surfaces. This wombat had lived on soft surfaces in an urban back yard her whole life. She eventually escaped and unfortunately had no skills to cope with the world outside.



## **Assesment and euthanasia**

In assessing a manged wombat for euthanasia the following should be taken into account:

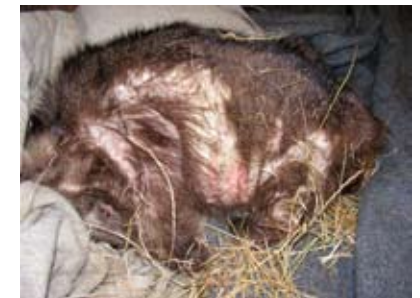### ***- the extent of mange coverage on the wombat.***

Remember that the mange coverage on a wombat is not always easily observed.

The wombat to the right has thickened crust on the front shoulders and about the neck. She had been attacked by three large dogs and had a velvet joey in the pouch. Her mange spread did not appear significant but the photo below illustrates how far down the sides of her body the mange actually had taken hold.



The pattern of fur loss, that continues to occur during treatment, is a clear indicator of the extent of spread.

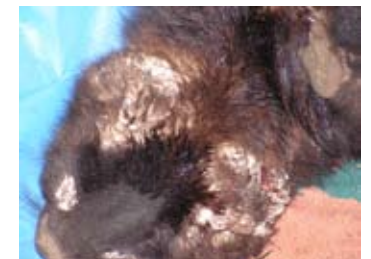

She, and her joey, were released after 14 months in care.

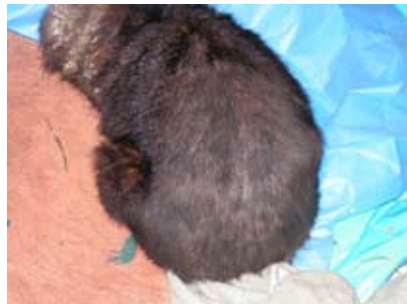### ***- the thickness of crust of the wombat***

The crust can grow very thick - but not always. It can also appear to be quite isolated to the front half of the body.

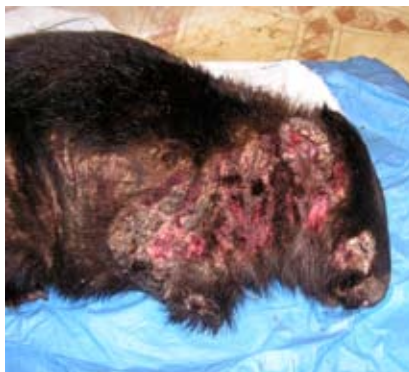The thickness of the crust on the wombat to the right means that there is a massive infestation of mites, and that the wombat has been infested for quite some time.



This is the same wombat from behind and it appears that her mange is not wide spread. The main thing to remember here is that the wombat has had that thick crust on its fore body for quite some time and the chances are that the integrity of the skin underneath the crust has been severely compromised by fungus and bacteria.



Once this wombat had been washed to remove crust the condition of the skin and the extent of the spread was revealed. This is a terrible, painful raw open wound.



***- fissuring of the crust and skin***

Once the crust has built up, and as the wombat moves about, deep cracks, or fissures, appear in the skin. These become conduits for bacteria, invasion of maggots and fluid loss. They are also painful. Fissures will usually be in places where the skin folds.

This is a large fissure that has opened across the back and shoulders of the wombat.



Although the crusting is not thick the extent is severe and the wombat was euthanased.

***- the age of the wombat***

It is almost impossible to age an adult wombat. Xrays and necropsies may show wear in the joints that would indicate an old wombat. Older Joeys and young wombats with mange generally have a better chance of recovery.

This joey was approximately 10 months old when he arrived in care. His mange was extensive and he had large gauges on his face where he had removed the crust himself.



He was released after 6 months in care.

***- the weight and energy of the wombat***

Emaciated and lethragic manged wombats are most likely too ill to survive capture, transport and treatment.



Healthy weight



Thin

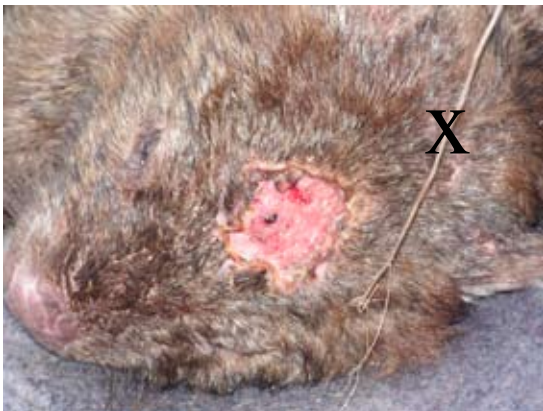
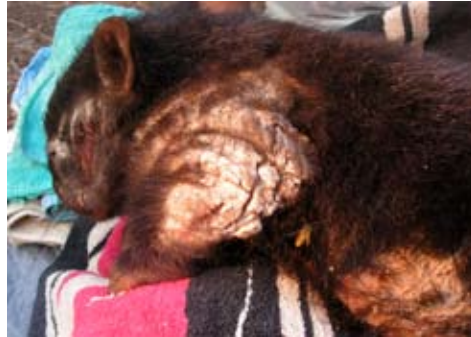

Reasonable weight & mange (not visible but extensive and crusted on inspection)

emaciated



What would be your euthanasia assesment of these two wombats?



When a wombat is to be euthased by shooting, please ensure it is done properly.

The wombat to the left was shot in the wrong place and was left alive. The bullet penetrated the upper pallet of the mouth.

X marks the correct spot.